

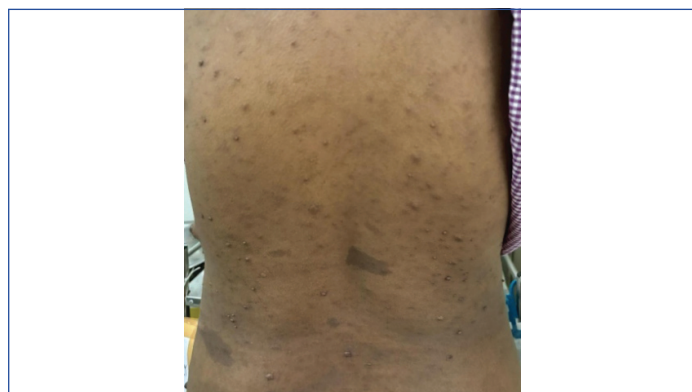Managing Sudden-onset Heart Block in a Neurofibromatosis Type 1 Patient undergoing Elective Caesarean Section

SANDIP BAHETI¹, GRACE MAMMEN²
Keywords: Atrioventricular block, Mobitz type 1, Pacemaker, Von Recklinghausen's disease

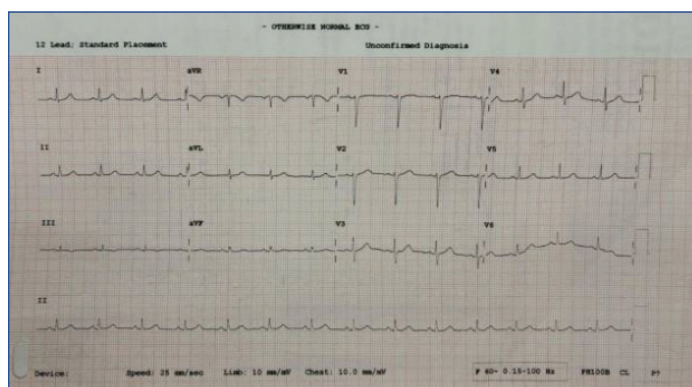
Dear Editor,

"A skilled physician is one who prevents illness." This wisdom from the Sefer Hasidim, a collection of Jewish aphorisms from the early 13th century, underscores a core tenet of the medical profession: Prevention is better than cure. This principle is particularly relevant in the operating room, where heightened awareness and rigorous monitoring are crucial for preventing complications and managing unforeseen events. This case highlights the prompt identification and management of sudden-onset heart block during an elective Lower Segment Caesarean Section (LSCS) in a patient with Neurofibromatosis Type 1 (NF1) and hypothyroidism, and a bad obstetric history that includes three spontaneous abortions and an ectopic pregnancy.

The patient, a 34-year-old female at 36 weeks of gestation, was a known case of NF1 since childhood and had been hypothyroid for six years, receiving regular treatment. Upon examination, the patient was vitally stable and exhibited characteristic café-au-lait lesions and neurofibromas all over her body [Table/Fig-1]. No other significant neurological findings were observed. All routine investigations, including thyroid profile, electrocardiogram, and 2D echocardiography tests, were within normal limits [Table/Fig-2].

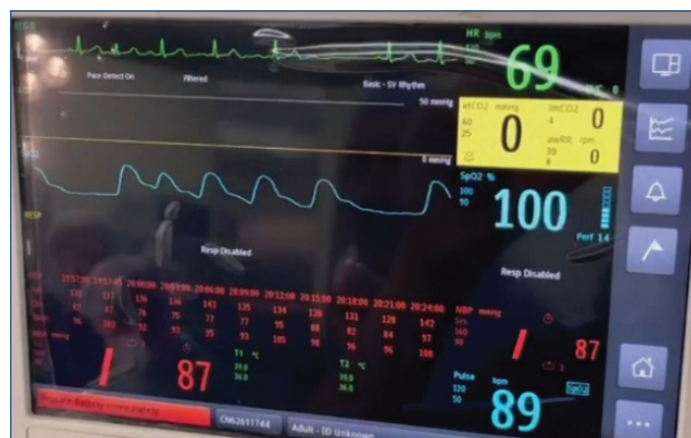

[Table/Fig-1]: Patient had characteristic lesions of NF1- café-au-lait spots and neurofibromas.

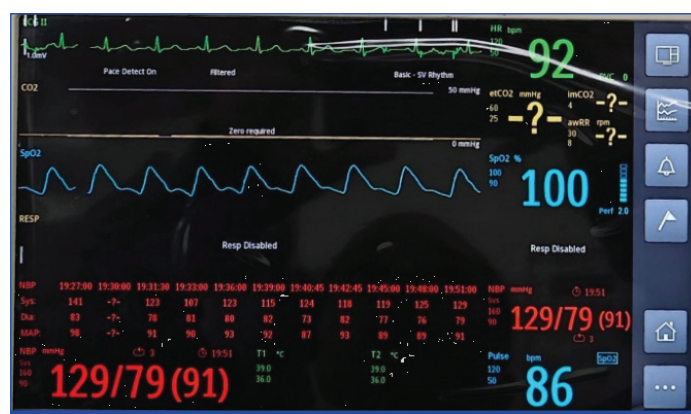

[Table/Fig-2]: Preoperative Electrocardiogram was normal.

Spinal anaesthesia was administered uneventfully for the surgery. Approximately 10 minutes after the delivery of the baby and the subsequent oxytocin infusion (20 IU slow intravenous drip), a Mobitz Type 1 heart block pattern [1] was observed on the intraoperative monitor [Table/Fig-3]. A stat dose of Inj. Atropine 0.6 mg was administered, and a pacemaker was kept on standby in case of progression to complete heart block. Within 2-3 minutes, the ECG rhythm normalised, with no further arrhythmias observed [Table/Fig-4]. The patient remained vitally stable throughout and was transferred to the Intensive Care Unit (ICU) for postoperative observation.



[Table/Fig-3]: Intraoperative Mobitz type 1 heart block.



[Table/Fig-4]: ECG was normalised postintervention.

NF1, also known as Von Recklinghausen's disease, is an autosomal dominant genetic disorder caused by a mutation in the NF1 gene on chromosome 17. This mutation inhibits the production of the protein neurofibromin, which regulates cell growth. The disorder is characterised by multiple café-au-lait macules, axillary and inguinal freckling, neurofibromas, and Lisch nodules. High-grade Atrioventricular (AV) block, though rare, is a serious cardiovascular complication of NF1, potentially associated with neurofibromas impacting the cardiac conduction system.

The development of arrhythmias in NF1 may also be linked to parasympathetic overactivity [1]. A study using Holter monitoring in NF1 patients found arrhythmias in 76% of cases, which included bradycardia, ventricular and supraventricular tachycardia, and extrasystoles [2]. Additionally, a case of biventricular failure with atrial fibrillation was linked to a neurofibroma in the interatrial septum [3]. While third-degree AV block is rare in adults, there is a documented paediatric case that progressed from sinus bradycardia and second-degree AV block to complete heart block [4]. More case reports are needed to further elucidate cardiac involvement in NF1 to help physicians provide effective treatment and prevent complications.

Treatment to prevent the progression of second-degree to complete heart block often requires permanent pacemaker implantation. Immediate interventions may include atropine, isoproterenol, or temporary pacing for symptomatic patients [5].

In this case of an NF patient, despite a normal preoperative evaluation, she still developed an unanticipated heart block. Prompt detection and treatment were key in preventing progression to complete block.

Reinforcing this principle of intraoperative vigilance is paramount in ensuring patient safety. While technological advancements, like real-time monitoring systems and automated alerts, enhance safety, they should complement—not replace—continuous clinical observation and critical thinking. By fostering a culture of relentless vigilance and teamwork, one can transform patient care and ensure that every heartbeat counts.

REFERENCES

[1] Verma S, Ahmed S, Gudapati SB, King DW, Meador KJ, Ahmed R. Arrhythmias in neurofibromatosis: A case report and review of the literature. *Cardiology*. 2001;95(3):167-69.

[2] Malmcrona R, Zoller M, Rembeck B. Heart rhythm in patients with neurofibromatosis type 1. *Cardiology*. 1996;87(4):300-02.

[3] Alaeddini J, Frater RW, Shirani J. Cardiac involvement in neurofibromatosis. *Tex Heart Inst J*. 2000;27(2):218-19.

[4] Neiman HL, Mena E, Holt JF, Stern AM, Perry BL. Neurofibromatosis and congenital heart disease. *Am J Roentgenol Radium Ther Nucl Med*. 1974;122(1):146-49.

[5] Gansé I, Goulahsen A, Laalou A, Issanga P, Cherei N, Karimi E, et al. Complete atrioventricular block revealing Von Recklinghausen Disease. *Sch J Med Case Rep*. 2019;7(12):757-59.

PARTICULARS OF CONTRIBUTORS:

1. Professor, Department of Anaesthesiology, Dr. D. Y. Patil Medical College and Research Centre, Dr. D. Y. Patil Vidyapeeth (Deemed to be University), Pimpri, Pune, Maharashtra, India.
2. Junior Resident, Department of Anaesthesiology, Dr. D. Y. Patil Medical College and Research Centre, Dr. D. Y. Patil Vidyapeeth (Deemed to be University), Pimpri, Pune, Maharashtra, India.

NAME, ADDRESS, E-MAIL ID OF THE CORRESPONDING AUTHOR:

Grace Mammen,
Junior Resident, Department of Anaesthesiology, Dr. D. Y. Patil Medical College,
Hospital and Research Centre, Pimpri, Pune-411018, Maharashtra, India.
E-mail: gracepune7@gmail.com

PLAGIARISM CHECKING METHODS: [\[Jain H et al.\]](#)

- Plagiarism X-checker: Feb 20, 2025
- Manual Googling: Mar 15, 2025
- iThenticate Software: Mar 18, 2025 (5%)

ETYMOLOGY: Author Origin

EMENDATIONS: 5

AUTHOR DECLARATION:

- Financial or Other Competing Interests: None
- Was informed consent obtained from the subjects involved in the study? No
- For any images presented appropriate consent has been obtained from the subjects. No

Date of Submission: **Feb 19, 2025**
Date of Peer Review: **Mar 10, 2025**
Date of Acceptance: **Mar 20, 2025**
Date of Publishing: **Apr 01, 2025**